

36. Harder BC, von Baltz S, Jonas JB, Schlichtenbrede FC. Intravitreal low-dosage bevacizumab for retinopathy of prematurity. *Acta Ophthalmol.* 2014;92:577-581.
37. Hanhart J, Tiosano L, Averbukh E, et al. Fellow eye effect of unilateral intravitreal bevacizumab injection in eyes with diabetic macular edema. *Eye.* 2014;28:646-653.

Footnotes and Financial Disclosures

Originally received: October 19, 2016.

Final revision: March 5, 2017.

Accepted: March 9, 2017.

Available online: April 13, 2017. Manuscript no. 2016-585.

Department of Ophthalmology, Xin Hua Hospital Affiliated to Shanghai Jiao Tong University School of Medicine, Shanghai, China.

Financial Disclosure(s):

The author(s) have no proprietary or commercial interest in any materials discussed in this article.

Support received from the National Natural Science Foundation of China, Beijing, China (81271045 and 81470642 to P.Z.; 81400408 to Y.X.; 81500725 to P.F.) and the Shanghai Science and Technology Commission, Shanghai, China (15XD1502800 to P.Z.). The sponsors and funding organization had no role in the design or conduct of this research.

Author Contributions:

Conception and design: Huang, Zhang, Fei, Ji, Zhao

Data collection: Huang, Peng, Li, Zhao

Analysis and interpretation: Huang, Zhang, Fei, Xu, Lyu, Zhao

Obtained funding: Not applicable

Overall responsibility: Huang, Xu, Lyu, Zhao

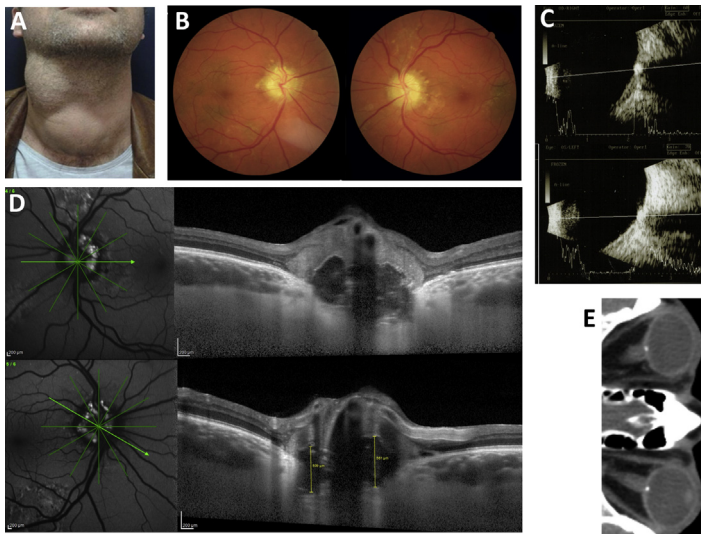
Abbreviations and Acronyms:

APROP = aggressive posterior retinopathy of prematurity; **BW** = birth weight; **GA** = gestational age; **IVB** = intravitreal injection of bevacizumab; **IVR** = intravitreal injection of ranibizumab; **NICU** = neonatal intensive care unit; **PMA** = postmenstrual age; **PNA** = postnatal age; **ROP** = retinopathy of prematurity; **VEGF** = vascular endothelial growth factor.

Correspondence:

Peiquan Zhao, MD, Department of Ophthalmology, Xin Hua Hospital Affiliated to Shanghai Jiao Tong University School of Medicine, Floor 11, Building 19, 1665 Kongjian Rd., 200092 Shanghai, China. E-mail: zhaopeiquan@126.com.

Pictures & Perspectives



Optic Nerve Head Drusen as a Rare Manifestation of Cowden Syndrome: Multimodal Imaging

A 50-year-old-man with diagnosed Cowden syndrome (CS) with *PTEN* mutation (p.Gly165X) and no family history presented with headaches and transitory visual obscurations and massive goiter (Fig 1A). Visual acuity was 20/30 bilaterally. Fundoscopy (Fig 1B) revealed blurred discs. Neuroimaging excluded ventriculomegaly/space-occupying lesions. Ultrasound (Fig 1C), autofluorescence, optical coherence tomography (Fig 1D), and computerized tomography (Fig 1E) showed voluminous optic nerve head drusen (ONHD). ONHD have been previously reported in only 2 patients with CS and multimodal imaging has not been provided. As ONHD have been associated with other phakomatosis and CS is a rare phakomatosis, this case provides supporting evidence that ONHD are a rare manifestation of CS.

Ivo GAMA, MD

LEONOR ALMEIDA, MD, PhD

University Hospital Santa Maria, Northern Lisbon Hospital Center; University of Lisbon, Faculty of Medicine, Lisbon, Portugal