

30. Villani A, Shore A, Wasserman JD, et al. Biochemical and imaging surveillance in germline TP53 mutation carriers with Li-Fraumeni syndrome: 11 year follow-up of a prospective observational study. *Lancet Oncol*. 2016;17:1295-1305.
31. Watts P, Westal C, Colpa L, et al. Visual results in children treated for macular retinoblastoma. *Eye*. 2002;16:75-80.
32. Lengyel D, Klainguti G, Mojon DS. Does amblyopia therapy make sense in eyes with severe organic defects?. *Klinische Monatsblätter für Augenheilkunde*. 2004;221:386-389.
33. Astudillo PP, Chan HS, Heon E, Gallie BL. Late-diagnosis retinoblastoma with germline mosaicism in an 8-year-old. *J AAPOS*. 2014;18:500-502.

Footnotes and Financial Disclosures

Originally received: January 6, 2017.

Final revision: January 27, 2017.

Accepted: January 30, 2017.

Available online: March 18, 2017.

Manuscript no. 2017-44.

¹ Department of Ophthalmology and Vision Sciences, Hospital for Sick Children, Toronto, Canada.

² Department of Ophthalmology, Faculty of Medicine, University of Alexandria, Alexandria, Egypt.

³ Department of Ophthalmology & Vision Sciences, Faculty of Medicine, University of Toronto, Toronto, Ontario, Canada.

⁴ Departments of Molecular Genetics and Medical Biophysics, Faculty of Medicine, University of Toronto, Toronto, Ontario, Canada.

⁵ Division of Visual Sciences, Toronto Western Research Institute, Toronto, Ontario, Canada.

Presented at: the American Academy of Ophthalmology Annual Meeting, Chicago, Illinois, October 17, 2016.

Financial Disclosure(s):

The author(s) have made the following disclosure(s): B.L.G.: unpaid medical director of Impact Genetics.

Author Contributions:

Conception and design: Soliman, VandenHoven, MacKeen, Héon, Gallie

Data collection: Soliman, VandenHoven, MacKeen

Analysis and interpretation: Soliman, VandenHoven, MacKeen, Héon, Gallie

Obtained funding: Not applicable

Overall responsibility: Soliman, VandenHoven, MacKeen, Héon, Gallie

Abbreviations/Acronyms:

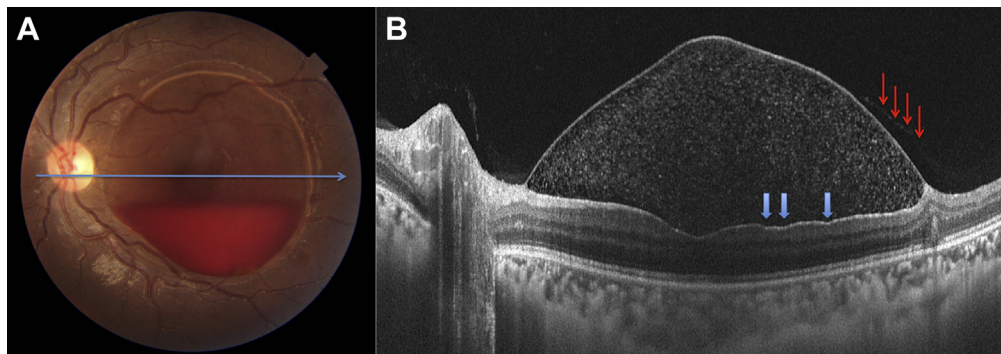
IIRC = International Intraocular Retinoblastoma Classification;

OCT = optical coherence tomography; **SVP** = sum voxel projection.

Correspondence:

Sameh E. Soliman, MD, 555 University Avenue, Room 7265, Toronto, Ontario M5G 1X8, Canada. E-mail: samehelsayedsoliman@yahoo.com.

Pictures & Perspectives



Dissociated Optic Nerve Fiber Layer in Subinternal Limiting Membrane Hemorrhage

A 20-year-old man, with known aplastic anemia, presented with decreased vision in his left eye due to subinternal limiting membrane (sub-ILM) hemorrhage (Fig 1A). Swept-source optical coherence tomography (SS-OCT, Fig 1B) showed multiple hyperreflective foci (related to the blood cells) below the dome-shaped hyperreflective membrane (ILM) along with a faint second layer corresponding to the posterior hyaloid (red arrows). The temporal macula showed irregular depressions (blue arrows) along the surface of retina, which are characteristic of dissociated optic nerve fiber layer (DONFL). This case supports mechanical separation of ILM from underlying retina as the main reason for DONFL appearance.

VINOD KUMAR, MS, FRCS (GLASG)

Dr RP Centre for Ophthalmic Sciences, All India Institute of Medical Sciences, New Delhi, India