

Footnotes and Financial Disclosures

Originally received: August 8, 2016.

Final revision: January 12, 2017.

Accepted: January 17, 2017.

Available online: February 14, 2017.

Manuscript no. 2016-44.

¹ Aravind Eye Hospital, Madurai, India.

² Altos Eye Physicians, Los Altos, California.

Financial Disclosure(s):

The author(s) have no proprietary or commercial interest in any materials discussed in this article.

Author Contributions:

Conception and design: Haripriya, Chang

Data collection: Haripriya, Ravindran

Analysis and interpretation: Haripriya, Chang, Ravindran

Obtained funding: Not applicable

Overall responsibility: Haripriya, Chang

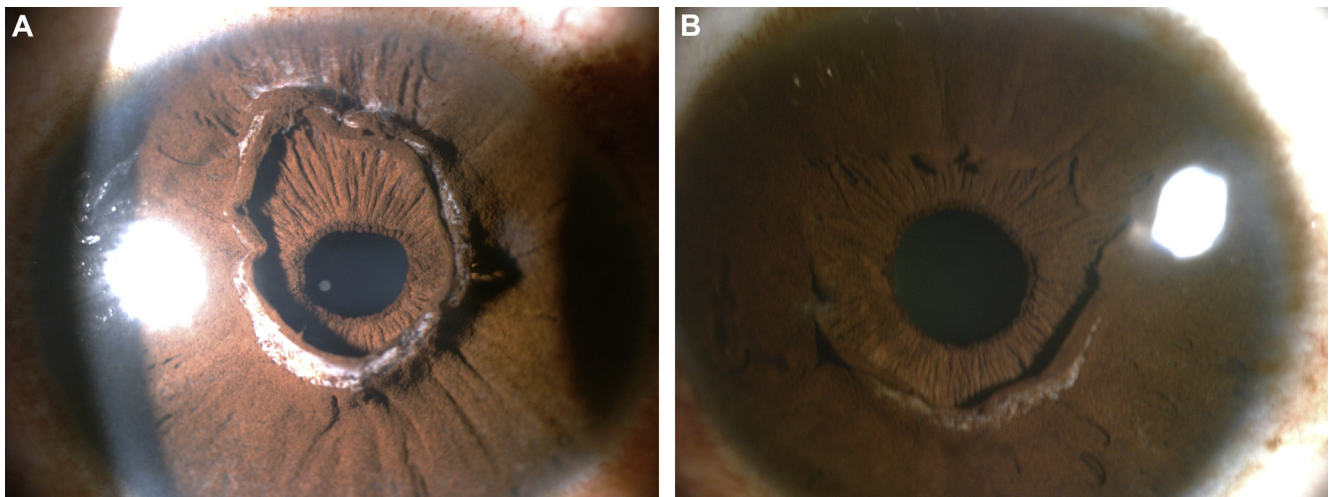
Abbreviations and Acronyms:

AECS = Aravind Eye Care System; **ASCRS** = American Society of Cataract and Refractive Surgery; **ESCRS** = European Society of Cataract & Refractive Surgeons; **IC** = intracameral; **IOL** = intraocular lens; **M-SICS** = manual small-incision cataract surgery; **PCR** = posterior capsular rupture.

Correspondence:

Aravind Haripriya, MD, Aravind Eye Hospital, 1, Anna Nagar, Madurai 625020, India. E-mail: haripriya@aravind.org.

Pictures & Perspectives



A Pseudopupil: Anterior Iris Stroma Hyperplasia

A 42-year-old African-American man presented for a routine examination, with no visual complaints. Slit-lamp microscopic examination of both eyes showed redundancy of the iris tissue arising from the collarettes. This pseudopupil was nonresponsive to mydriatics. Gonioscopic examination revealed no abnormalities of the angle. This anomaly is thought to arise from aberrant degeneration of the anterior tunica vasculosa lentis, which usually begins to resorb at 6 months during embryogenesis (Fig 1A, right eye; Fig 1B, left eye).

MATHIEU F. BAKHOUM, MD, PhD^{1,2}

JOHN M. ALEXANDER, MD^{1,2}

HENRY D. PERRY, MD^{1,3}

¹Nassau University Medical Center, Department of Ophthalmology, East Meadow, New York; ²Columbia University Medical Center, Department of Ophthalmology, New York, New York; ³Ophthalmic Consultants of Long Island, Long Island, New York