

## Footnotes and Financial Disclosures

Originally received: October 30, 2016.

Final revision: December 20, 2016.

Accepted: December 20, 2016.

Available online: January 31, 2017.

Manuscript no. 2016-694.

<sup>1</sup> Ocular Oncology Service, Wills Eye Hospital, Thomas Jefferson University, Philadelphia, Pennsylvania.

<sup>2</sup> Department of Genetics, University of Pennsylvania School of Medicine, Philadelphia, Pennsylvania.

Presented in part as The 2016 W. Richard Green Lecture of the Macula Society, Eden Roc, Florida, February 25, 2016 (CLS).

Financial Disclosure(s):

The author(s) have no proprietary or commercial interest in any materials discussed in this article.

Support provided by Eye Tumor Research Foundation, Philadelphia, Pennsylvania (C.L.S., J.A.S.). The funders had no role in the design and conduct of the study, in the collection, analysis, and interpretation of the data, and in the preparation, review, or approval of the manuscript. C.L.S. has had full access to all the data in the study and takes responsibility for the integrity of the data and the accuracy of the data analysis.

Biostatistics performed by Rishita Nutheti, PhD, biostatistician, Hyderabad, India.

Author Contributions:

Conception and design: Shields, Say, Hasanreisoglu, Saktanasate, Ganguly  
Data collection: Shields, Say, Hasanreisoglu, Saktanasate, Lawson, Landy, Badami, Sivalingam, Mashayekhi, Shields, Ganguly

Analysis and interpretation: Shields, Say, Hasanreisoglu, Saktanasate, Mashayekhi, Shields, Ganguly

Obtained funding: Not applicable

Overall responsibility: Shields, Say, Hasanreisoglu, Saktanasate, Lawson, Landy, Badami, Sivalingam, Mashayekhi, Shields, Ganguly

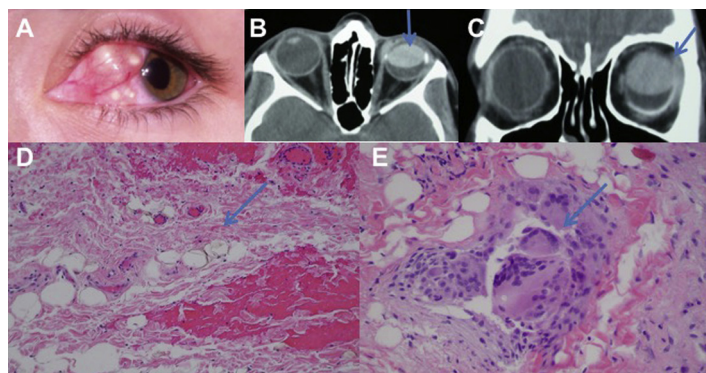
Abbreviations and Acronyms:

**D3** = disomy 3; **D368** = disomy 3, 6, and 8; **FNAB** = fine-needle aspiration biopsy; **ND** = not disomy; **OR** = odds ratio; **VA** = visual acuity.

Correspondence:

Carol L. Shields, MD, Ocular Oncology Service, 840 Walnut Street, Suite 1440, Philadelphia, PA 19107. E-mail: [carolshields@gmail.com](mailto:carolshields@gmail.com).

## Pictures & Perspectives



### Subconjunctival Granulomas from Extrascleral Silicon Oil Leak

An 18-year-old woman sustained left eye trauma and underwent repair via pars plana vitrectomy (PPV) and placement of silicon oil (SO). She subsequently developed phthisis bulbi and presented with complaints of a blind painful eye. Examination revealed multiple yellow granulomas in the subconjunctival space (Fig 1A). Computed tomography showed that SO had migrated into the anterior segment (Fig 1B), as well as into the orbit through a scleral PPV port (Fig 1C). The patient underwent enucleation with orbital debridement and orbital implant placement. Histopathology revealed SO (Fig 1D) and multinucleated giant cells (Fig 1E) within the ocular adnexal tissues.

NORA SILVERMAN, MD, PhD<sup>1</sup>

JOHN W. SHORE, MD, FACS<sup>2</sup>

ROMAN SHINDER, MD, FACS<sup>1,2</sup>

<sup>1</sup>SUNY Downstate Medical Center, Brooklyn, New York; <sup>2</sup>Texas Oculoplastic Consultants, Austin, Texas