

Footnotes and Financial Disclosures

Originally received: October 4, 2016.

Final revision: December 15, 2016.

Accepted: December 16, 2016.

Available online: January 30, 2017.

Manuscript no. 2016-248.

¹ Division of Ophthalmology, NorthShore University Health System, Glenbrook Hospital, Glenview, Illinois.

² University of Chicago, Chicago, Illinois.

Presented at: the American Academy of Ophthalmology Annual Meeting, October 15–18, 2016, Chicago, Illinois.

Financial Disclosure(s):

The author(s) have made the following disclosure(s): R.A.B.: Employed by the NorthShore University Health Care System.

Supported by intramural research funds from the Division of Ophthalmology, NorthShore University Health Care System. The funding organization participated in the data collection.

Author Contributions:

Conception and design: Braslow, Shiloach

Data collection: Braslow, Shiloach

Analysis and interpretation: Braslow

Obtained funding: Not applicable

Overall responsibility: Braslow, Macsai

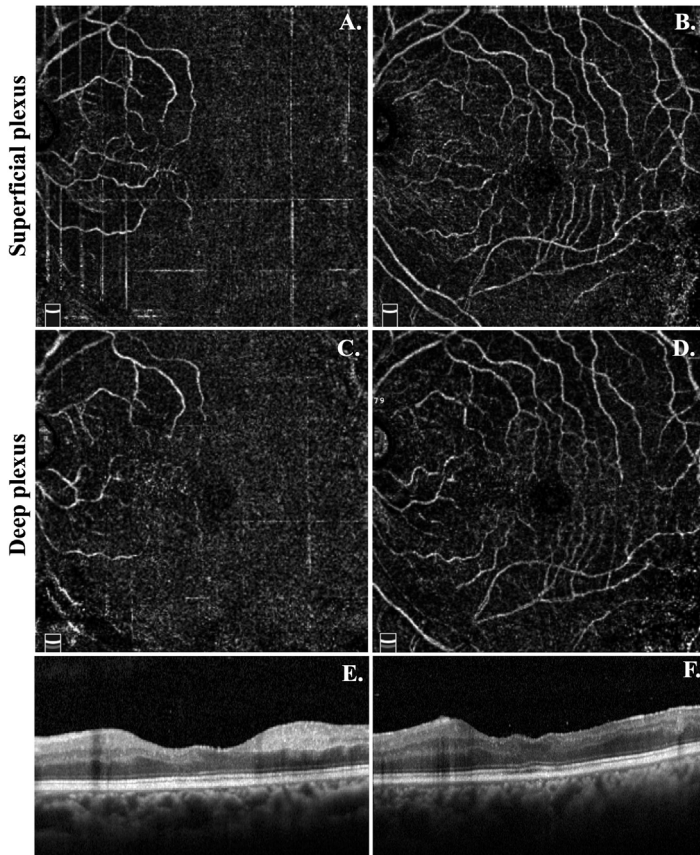
Abbreviations and Acronyms:

EMR = electronic medical record; **HCQ** = hydroxychloroquine.

Correspondence:

Rebekah A. Braslow, MD, Division of Ophthalmology, NorthShore University Health System, Glenbrook Hospital, 2050 Pfungsten Road, Glenview, IL 60026. E-mail: rbraslow@northshore.org.

Pictures & Perspectives



Optical Coherence Tomography Angiography of a Central Retinal Artery Occlusion Before and After Anterior Chamber Paracentesis

A 74-year-old man presented 6 hours after sudden painless vision loss in the left eye. He had finger counting vision, normal intraocular pressure, and an afferent pupillary defect. Diagnosis of central retinal artery occlusion was made. Optical coherence tomography angiography performed before (Fig 1A, C) and immediately after (Fig 1B, D) anterior chamber paracentesis showed dramatic improvement in macular perfusion. Vision was 20/70 at the 1-month visit. Optical coherence tomography at presentation showed acute inner retinal opacification (Fig 1E), whereas 10 months later (Fig 1F) it illustrated partial preservation of inner retinal laminations, which we attributed to reperfusion of superficial and deep retinal circulations.

CHRISTOPHER K. HWANG, MD, PhD

ANTON M. KOLOMEYER, MD, PhD

ALEXANDER J. BRUCKER, MD

Department of Ophthalmology, Scheie Eye Institute, University of Pennsylvania, Philadelphia, Pennsylvania