

9. Brodie SE, Paulus YM, Patel M, et al. ERG monitoring of retinal function during systemic chemotherapy for retinoblastoma. *Br J Ophthalmol.* 2012;96:877-880.
10. Liu CY, Jonna G, Francis JH, et al. Non-selectivity of ERG reductions in eyes treated for retinoblastoma. *Doc Ophthalmol.* 2014;128:13-23.
11. Munier FL, Soliman S, Moulin AP, et al. Profiling safety of intravitreal injections for retinoblastoma using an anti-reflux procedure and sterilisation of the needle track. *Br J Ophthalmol.* 2012;96:1084-1087.
12. Smith SJ, Smith BD. Evaluating the risk of extraocular tumour spread following intravitreal injection therapy for retinoblastoma: a systematic review. *Br J Ophthalmol.* 2013;97(10):1231-1236.
13. Shields CL, Manjandavida FP, Arepalli S, et al. Intravitreal melphalan for persistent or recurrent retinoblastoma vitreous seeds: preliminary results. *JAMA Ophthalmol.* 2014;132:319-325.
14. Ghassemi F, Shields CL, Ghadimi H, et al. Combined intravitreal melphalan and topotecan for refractory or recurrent vitreous seeding from retinoblastoma. *JAMA Ophthalmol.* 2014;132:936-941.
15. Zadnik K, Mutti DO, Mitchell GL, et al. Normal eye growth in emmetropic schoolchildren. *Optom Vis Sci.* 2004;81:819-828.
16. Schaiquevich P, Buitrago E, Taich P, et al. Pharmacokinetic analysis of melphalan after superselective ophthalmic artery infusion in preclinical models and retinoblastoma patients. *Invest Ophthalmol Vis Sci.* 2012;53:4205-4212.

## Footnotes and Financial Disclosures

Originally received: November 1, 2016.

Final revision: December 6, 2016.

Accepted: December 12, 2016.

Available online: January 14, 2017.

Manuscript no. 2016-681.

<sup>1</sup> Ophthalmic Oncology Service, Memorial Sloan-Kettering Cancer Center, New York, New York.

<sup>2</sup> Weill-Cornell Medical Center, New York, New York.

<sup>3</sup> Icahn School of Medicine at Mount Sinai, New York, New York.

<sup>4</sup> Department of Epidemiology & Biostatistics, Memorial Sloan-Kettering Cancer Center, New York, New York.

Presented at: the American Academy of Ophthalmology meeting, October 15–18, 2016, Chicago, Illinois.

Financial Disclosure(s):

The author(s) have made the following disclosure(s): B.M.: Consultant – Aura Biosciences, Inc.

Supported by the Fund for Ophthalmic Knowledge, the New York Community Trust, Research to Prevent Blindness and Cancer Center Support Grant (P30 CA008748). The sponsor or funding organization had no role in the design or conduct of this research.

Author Contributions:

Conception and design: Francis, Abramson

Data collection: Francis, Brodie, Marr, Mondesire-Crump

Analysis and interpretation: Francis, Zabor, Abramson

Obtained funding: none

Overall responsibility: Francis, Brodie, Abramson

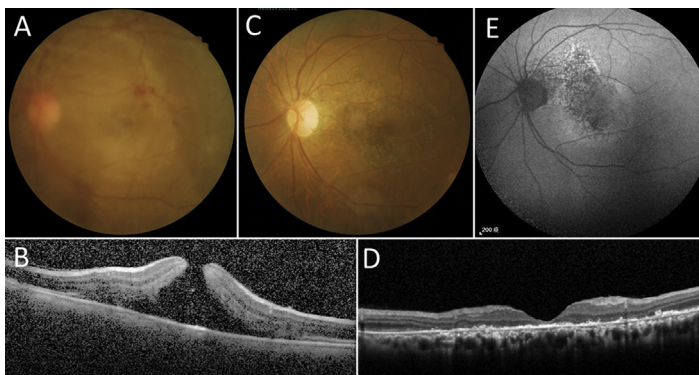
Abbreviations and Acronyms:

**ERG** = electroretinography; **OAC** = ophthalmic artery chemosurgery.

Correspondence:

Jasmine H. Francis, MD, FACS, Memorial Sloan Kettering Cancer Center, 1275 York Avenue, New York, NY 10065. E-mail: [francij1@mskcc.org](mailto:francij1@mskcc.org).

## Pictures & Perspectives



### Traumatic Maculopathy with Macular Hole

A 61-year-old man sustained blunt injury to his left eye, decreasing visual acuity to count fingers. Examination revealed mild vitreous hemorrhage, Berlin's edema with retinal hemorrhage, and a macular hole (Fig 1A). Spectral-domain optical coherence tomography (SD OCT) demonstrated a full-thickness macular hole with increased parafoveal thickness (Fig 1B). Two months later, his vision was 2/200, and examination showed resolution of macular edema with spontaneous closure of traumatic macular hole (Fig 1C). Spectral-domain OCT demonstrated loss of the ellipsoidal zone and external limiting membrane (Fig 1D). Fundus autofluorescence revealed interposed, reduced, and increased macular and peripapillary autofluorescence (Fig 1E).

KUAN-JEN CHEN, MD

Department of Ophthalmology, Chang Gung Memorial Hospital, Chang Gung University College of Medicine, Tayouan, Taiwan