

Footnotes and Financial Disclosures

Originally received: March 5, 2016.

Final revision: July 9, 2016.

Accepted: July 10, 2016.

Available online: August 15, 2016. Manuscript no. 2016-462.

¹ London School of Hygiene and Tropical Medicine, London, United Kingdom.

² Aravind Eye Hospital, Madurai, Tamil Nadu, India.

³ Aravind Medical Research Foundation, Madurai, Tamil Nadu, India.

⁴ Moorfields Eye Hospital, London, United Kingdom.

Presented at: Royal College of Ophthalmologists Annual Congress, Liverpool, UK, May 2015.

Financial Disclosure(s):

The author(s) have made the following disclosure(s): J.D.C.: Grant — International Health PhD Fellowship, grant no. 097437/Z/11/Z.

Supported by the Wellcome Trust, London, United Kingdom. The sponsor or funding organization had no role in the design or conduct of this research.

Author Contributions:

Conception and design: Chidambaram, Prajna, Larke, Palepu, Lalitha, Hau, Burton

Analysis and interpretation: Chidambaram Prajna, Larke, Carnit, Vesaluoma, Hau, Burton

Data collection: Chidambaram, Prajna, Palepu, Lanjewar, Shah, Elakkiya, Lalitha, Carnit, Vesaluoma, Mason, Hau, Burton

Obtained funding: Not applicable

Overall responsibility: Chidambaram, Prajna, Larke, Palepu, Lanjewar, Shah, Elakkiya, Lalitha, Carnit, Vesaluoma, Mason, Hau, Burton

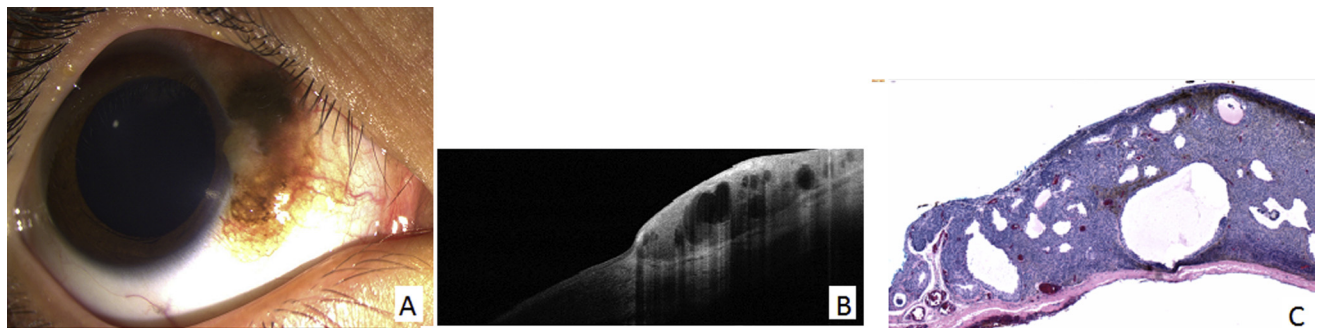
Abbreviations and Acronyms:

AK = *Acanthamoeba* keratitis; **BA** = blood agar; **CI** = confidence interval; **IVCM** = in vivo confocal microscopy; **MK** = microbial keratitis; **NPV** = negative predictive value; **PDA** = potato dextrose agar; **PPV** = positive predictive value.

Correspondence:

Jaya D. Chidambaram, MBBS, MRCOphth, International Centre for Eye Health, London School of Hygiene and Tropical Medicine, Room K390, Keppel Street, London WC1E 7HT, United Kingdom. E-mail: Jaya.Chidambaram@Lshhtm.ac.uk.

Pictures & Perspectives



Cystic Compound Melanocytic Nevus in a Pediatric Patient

An 8-year-old Brazilian girl presented with a pigmented conjunctival lesion of her right eye since birth that had been progressively enlarging in size and darkening in pigmentation (Fig 1A). Anterior segment optical coherence tomography (OCT) (Fig 1B) was concerning for possible scleral invasion. The lesion was excised and histopathologic analysis (H&E) demonstrated cystic compound melanocytic nevus with nests of nevus cells in the junctional and subepithelial layers (Fig 1C). There was no evidence of malignancy based on Mart-1, Ki-67, and MITF-1 stains.

CATHERINE S. CHOI, MD

PEDRAM HAMRAH, MD

NORA LAVER, MD

Department of Ophthalmology, Tufts Medical Center, Boston, Massachusetts