

York, New York (J.H.L.). The funding organization had no role in the design or conduct of this research.

Author Contributions:

Conception and design: M.O.Price, Calhoun, Kollman, F.W.Price, Lass

Analysis and interpretation: M.O.Price, Calhoun, Kollman, F.W.Price, Lass

Data collection: M.O.Price, F.W.Price

Obtained funding: Lass

Overall responsibility: M.O.Price, Calhoun, Kollman, F.W.Price, Lass

Abbreviations and Acronyms:

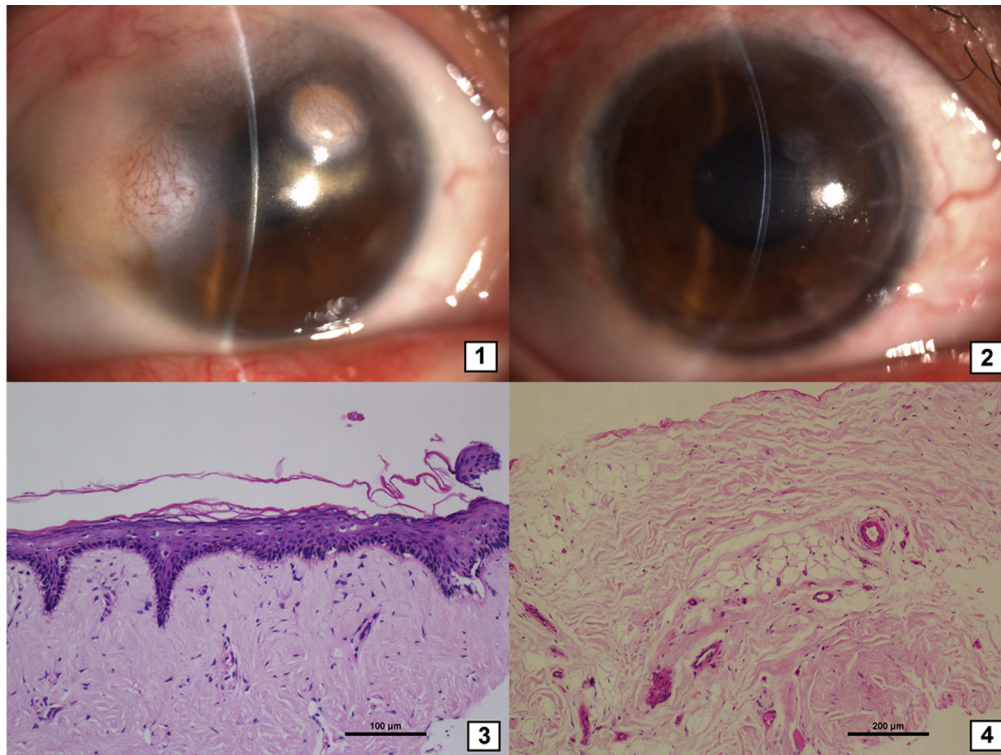
**CDS** = Cornea Donor Study; **DMEK** = Descemet membrane endothelial keratoplasty; **DSEK** = Descemet stripping endothelial keratoplasty; **ECD** = endothelial cell density; **EK** = endothelial keratoplasty; **FECD** = Fuchs' endothelial corneal dystrophy; **MCMC** = Markov chain Monte Carlo; **PACE** = pseudophakic or aphakic corneal edema; **PK** = penetrating keratoplasty; **SD** = standard deviation; **SMAS** = Specular Microscopy Ancillary Study.

Correspondence:

Marianne O. Price, PhD, Cornea Research Foundation of America, 9002 North Meridian Street, Suite 212, Indianapolis, IN 46260. E-mail: [mprice@cornea.org](mailto:mprice@cornea.org).

## Pictures & Perspectives

---



### Multiple Ocular Dermoids

A 22-year-old woman presented with several masses in her right eye that had been present since birth (Fig 1). The vascularized masses were surrounded by deep corneal opacities. The patient had no systemic abnormalities. Excision and deep anterior lamellar keratoplasty were performed (Fig 2). The diagnosis of multiple ocular dermoids was confirmed by histopathology, which showed keratinized squamous epithelium and fibrous connective tissue (Figs 3-4).

WENJIA XIE, MD, OD

YU-FENG YAO, MD, PhD

Department of Ophthalmology, Sir Run Run Shaw Hospital, Zhejiang University School of Medicine, Hangzhou, China