

Diagnosis and Management of Central Retinal Artery Occlusion

Central retinal artery occlusion (CRAO) is an ocular emergency. Patients typically present with profound, acute, painless monocular visual loss—with 80% of affected individuals having a final visual acuity of counting fingers or worse. CRAO is the ocular analogue of a cerebral stroke—and, as such, the clinical approach and management are relatively similar to the management of stroke, in which clinicians treat the acute event, identify the site of vascular occlusion, and try to prevent further occurrences. The incidence of CRAO is approximately 1 to 2 in 100,000,^{1,2} with a male predominance and mean age of 60-65 years.

Anatomy

The retina receives a dual blood supply, with the inner retina supplied by the central retinal artery and the outer retina supplied by the choroidal circulation via branches of the posterior ciliary arteries.

Both sets of arteries arise from the ophthalmic artery, the first branch of the internal carotid artery just as it exits the cavernous sinus. The ophthalmic artery passes through the optic canal inferolaterally to the optic nerve.

On entering the orbit, the central retinal artery leaves the ophthalmic artery and travels within the optic nerve, after which it enters the eye, where it is subjected to intraocular pressure changes.

Approximately 15%-30% of the population has a cilioretinal artery, a branch of the short posterior ciliary artery. It supplies blood to part or all of the fovea. If a CRAO occurs in such eyes, the cilioretinal artery is spared, typically preserving visual acuity at 20/50 or better, although peripheral visual field is still severely impaired.

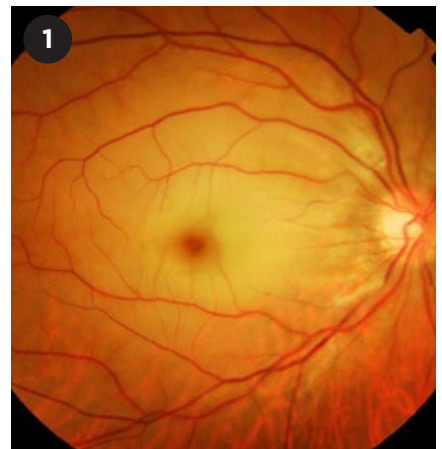
Risk Factors

The major risk factors for CRAO can be divided into nonarteritic and arteritic.

Nonarteritic. More than 90% of CRAOs are nonarteritic in origin. Ipsilateral carotid artery atherosclerosis is the most common cause of retinal artery occlusion with a prevalence as high as 70% reported among patients with CRAO or branch retinal artery occlusion.^{3,4}

Other causes of nonarteritic retinal artery occlusion include cardiogenic embolism, hematological conditions (sickle cell disease, hypercoagulable states, leukemia, lymphoma, etc.), and other vascular diseases, such as carotid artery dissection, moyamoya disease, and Fabry disease.

Arteritic. CRAO of arteritic etiology is mostly caused by giant cell arteritis, although other vasculitic disorders such as Susac syndrome, systemic lupus erythematosus, polyarteritis nodosa, and granulomatosis with polyangiitis have also been associated with retinal artery occlusion.



CLASSIC PRESENTATION. Fundus photograph of a patient with right central retinal artery occlusion, evidenced by widespread ischemic retinal whitening with a classic cherry red spot.

Signs and Symptoms

Patients with CRAO usually present with sudden and profound unilateral loss of vision. In a study of 260 eyes with CRAO, 74% had presenting visual acuity of counting fingers or worse, while the remainder showed some degree of macular sparing that perfused the fovea with resultant better visual acuity.⁵

On examination, a relative afferent pupillary defect occurs regardless of the visual acuity or macular sparing. Classic ophthalmoscopic signs include retinal edema (ischemic retinal whitening), cherry red spot (due to underlying normal choroidal circulation [Fig. 1]), retinal arteriolar attenuation, and, in the acute phase, segmentation of blood in retinal arterioles (also known as box-carring). A retinal embolus may be visible in up to 40% of patients.⁶ The

BY **SHAUN SIM, MD**, AND **DANIEL S.W. TING, MD, PHD**. EDITED BY SHARON FEKRAT, MD, AND INGRID U. SCOTT, MD, MPH.

embolic material can be a shiny cholesterol plaque, gray-white platelet plaque, or white calcium plaque.

Associated signs and symptoms may point toward a specific etiology such as headache and scalp tenderness in giant cell arteritis, or contralateral sensory or motor deficits in carotid artery disease.

Evaluation

In the acute phase of CRAO, optical coherence tomography will show thickening of the inner retina with sparing of the outer retinal layers. Subsequent retinal atrophy and thinning occurs after approximately 6 weeks.

Fundus fluorescein angiography in the acute phase reveals normal choroidal filling with delayed or absent filling of the central retinal artery. If the choroidal circulation is also impaired, especially in patients over the age of 50 with CRAO and no visible retinal emboli, giant cell arteritis must be ruled out through laboratory tests such as erythrocyte sedimentation rate (ESR), complete blood count, and C-reactive protein.

Systemic evaluation is critical for CRAO patients. They require carotid artery imaging (carotid duplex ultrasound, cervical magnetic resonance imaging, or computed tomography angiography), as the most common cause of CRAO is carotid atherosclerosis. A cardiac evaluation in the form of echocardiography and Holter monitoring may be required in patients in whom carotid disease has been ruled out.

Treatment

CRAO is a medical emergency. Prompt referral for stroke evaluation is necessary in order to minimize risk of secondary ischemic events such as cerebral or myocardial infarction.

In the acute setting, therapy is directed at resolving the CRAO and maximizing visual outcome. Experimental studies suggest no detectable retinal damage in primate models with CRAO, if retinal blood flow is restored within 90 minutes. Subsequent partial recovery may be possible if ischemia is reversed within 240 minutes.⁷ However, occlusions lasting longer than 240 minutes produce irreversible damage.

Table 1: Treatment Options for CRAO

TREATMENT	MECHANISM OF ACTION
Pharmacological	
IV* acetazolamide	Reduce intraocular pressure
IV mannitol	Reduce intraocular pressure
Topical antiglaucoma medications	Reduce intraocular pressure
Pentoxifylline	Vasodilation to increase blood oxygen content
Inhalation of carbogen	Vasodilation to increase blood oxygen content
Sublingual isosorbide dinitrate	Vasodilation to increase blood oxygen content
IV methylprednisolone	Reduce retinal edema, only given in arteritic CRAO
IV or intra-arterial recombinant tissue plasminogen activator (rt-PA)	Thrombolytic therapy to dissolve clot
Hyperbaric oxygen therapy	Increase blood oxygen tension
Surgery/Procedures	
Anterior chamber paracentesis	Reduce intraocular pressure
Ocular massage	Fluctuation in intraocular pressure to mechanically dislodge clot
Nd:YAG laser embolectomy	Lyse or dislodge the clot
Pars plana vitrectomy	Surgical removal of the clot
Lifestyle Modification	
Optimization of atherosclerotic diseases	Secondary prevention

*IV = Intravenous

SOURCE: Developed by the authors.

Despite the multitude of treatments purported to be of benefit in acute CRAO, there has been no conclusive evidence to support their use. Table 1 summarizes the possible treatment options.

Complications

Neovascularization may occur in patients with CRAO. It may involve the retina, iris, or iridocorneal angle. There is a debate about the association of CRAO and the development of neovascular glaucoma. A prospective study of 33 patients established a temporal relationship between CRAO and neovascular glaucoma in 15% of cases.⁸ These results are corroborated by a retrospective study that showed a mean of 8.5 weeks from diagnosis to clinically evident neovascularization.⁹ However, a prospective study of 232 eyes found

neovascularization in 2.5% of cases, and the authors found that there was no causal relationship.¹⁰

The development of neovascularization necessitates prompt panretinal laser photocoagulation to decrease retinal oxygen demand.

Conclusion

CRAO is an ophthalmic and medical emergency. The causes of and risk factors for CRAO are similar to those of cerebrovascular events. Hence, patients with CRAO must be evaluated promptly for stroke to minimize secondary ischemic events. Despite the grim prognosis for CRAO, efforts to restore vision—no matter which therapy is used—should be instituted, preferably within 4 hours of symptoms.

1 Leavitt JA et al. *Am J Ophthalmol.* 2011;152(5):

820-823.

2 Rumelt S et al. *Am J Ophthalmol.* 1999;128(6):733-738.

3 Ahuja RM et al. *Stroke.* 1999;30(8):1506-1509.

4 Babikian V et al. *Cerebrovasc Dis.* 2001;12:108-113.

5 Hayreh SS, Zimmerman MB. *Am J Ophthalmol.* 2005;140(3):376.e1-e18.

6 Sharma S et al. *Arch Ophthalmol.* 1998;116(12):1602.

7 Hayreh SS et al. *Ophthalmology.* 1980;87(1):75-78.

8 Duker JS et al. *Arch Ophthalmol.* 1991;109(3):339-342.

9 Rudkin AK et al. *Eur J Ophthalmol.* 2010;20(6):1042-1046.

10 Hayreh SS et al. *Ophthalmology.* 2009;116(10):1928-1936.

Dr. Sim is an ophthalmology resident at the Singapore National Eye Centre. Dr. Ting is associate consultant at the Singapore National Eye Centre and assistant professor at Duke-National University Singapore (Duke-NUS) Medical School. *Financial disclosures: None.* The authors would like to acknowledge Mr. Kasi Sandhanam, the ocular imaging specialist from Singapore National Eye Centre, for providing the color fundus photo.

Write an Ophthalmic Pearls Article


Interested in sharing with your colleagues an overview of a specific disease entity based on the latest evidence?

Pearls articles typically offer step-by-step summaries of etiology, diagnosis, treatment, and follow-up.

To get started, you need only a few things:

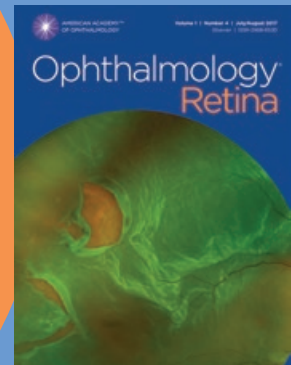
- a great topic
- a faculty advisor to review your manuscript and add his/her pearls from clinical experience
- a copy of the Writers Guidelines and the Pearls Checklist to ensure that all key requirements have been met. Find them at aao.org/eyenet/write-for-us.

Are you a resident? A resident article published in the Ophthalmic Pearls section will satisfy the RRC requirements for resident scholarly activity.



AMERICAN ACADEMY™
OF OPHTHALMOLOGY

High-quality
research from the
world's leading
ophthalmic journal



The Academy's newest scientific publication, *Ophthalmology*® *Retina*, focuses on advances in medical drug treatment, surgery and technology for retina-related diseases and conditions.

Subscribe at aao.org/store.

Protecting Sight. Empowering Lives.™