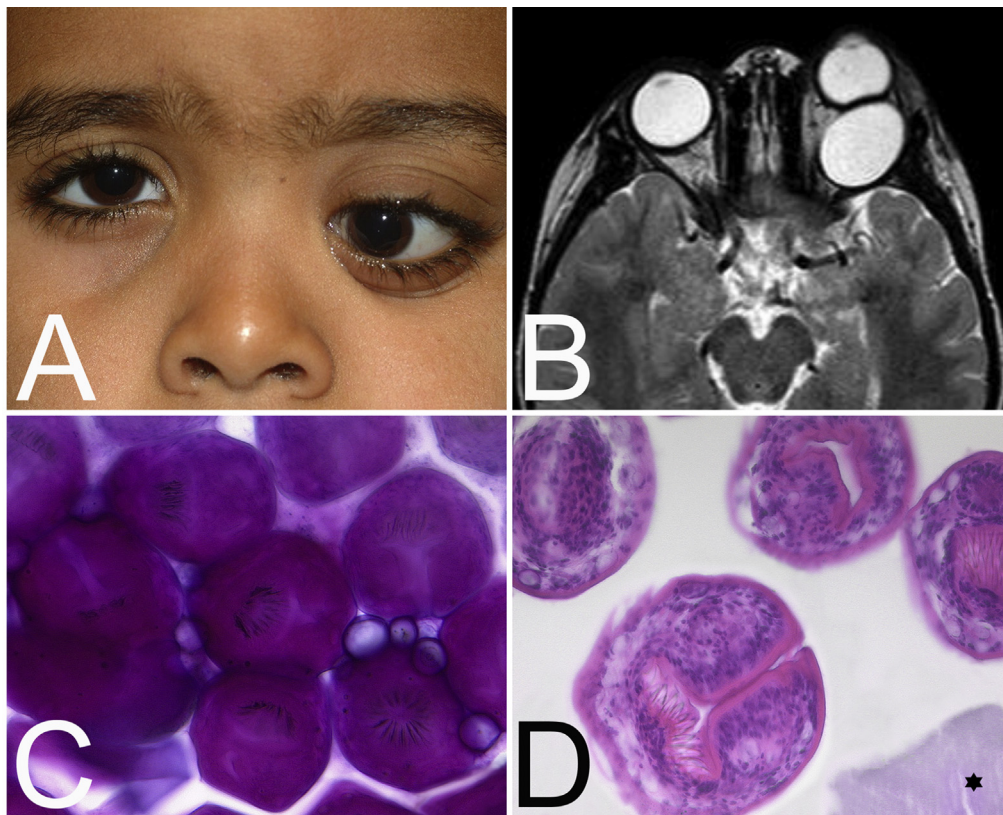


9. Prober C, Kolars J, First L, et al. A plea to reassess the role of United States Medical Licensing Examination Step 1 scores in residency selection. *Acad Med* 2016;91:12–4.

10. National Resident Matching Program. Charting Outcomes in the Match. Available at: <http://www.nrmp.org/new-charting-outcomes-match/>. Accessed March 15, 2016.

Pictures & Perspectives



Primary Orbital Hydatid Cyst

A 5-year-old girl presented with painless proptosis and downward displacement of her left eye for 2 years (Fig 1A). Magnetic resonance imaging demonstrated a large cyst-like retrobulbar mass (Fig 1B). Serology for echinococcosis was negative. After surgical removal by lateral transosseous orbitotomy, histopathology revealed multiple scolices provided with hooklets (Fig 1C and D) adjacent to a thick membrane (Fig 1D, asterisk), consistent with a hydatid cyst of the larval form of the dog tapeworm *Echinococcus granulosus*. Hydatid cysts rarely occur isolated in the orbit. Postoperative therapy included 2 cycles of albendazole for 28 days.

ANNA M. LENTZSCH, MD¹

HEIKE GÖBEL, MD²

LUDWIG M. HEINDL, MD¹

¹Department of Ophthalmology, University of Cologne, Cologne, Germany; ²Department of Pathology, University of Cologne, Cologne, Germany