

Cytomegalovirus Anterior Uveitis in Immunocompetent Patients

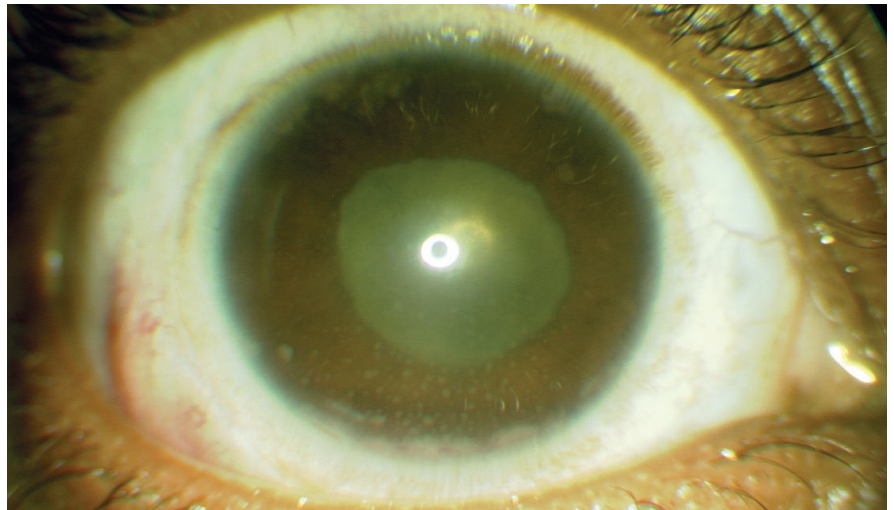
Cytomegalovirus (CMV) is part of the Herpesviridae family of DNA viruses, which also includes herpes simplex virus (HSV), varicella-zoster virus (VZV), and Epstein-Barr virus. Herpesviruses can induce keratitis, anterior uveitis, scleritis, and retinitis. Herpetic anterior uveitis commonly causes endotheliitis, stromal and epithelial keratitis, and iris stromal atrophy, as well as an increase in intraocular pressure (IOP), likely due to trabeculitis-related impairment of aqueous outflow.

Although CMV exposure is nearly ubiquitous, the virus typically does not cause ophthalmic disease in immunocompetent hosts. However, CMV is widely known to cause a viral retinitis in patients with immune compromise, most commonly in AIDS.

Recently, in immunocompetent patients, CMV has been recognized as a rare cause of persistent anterior uveitis accompanied by severe increase in IOP.¹ A number of authors have suggested that CMV infection of the anterior chamber may be responsible for Posner-Schlossman syndrome, also called glaucomatocyclitic crisis.² (See “CMV and Posner-Schlossman Syndrome.”)

Patient Presentation

CMV anterior uveitis in immunocompetent patients typically presents with blurred vision, eye pain, and conjunctival injection; and patients may expe-



CMV SIGNS. External photograph of the right eye of a patient with CMV anterior uveitis demonstrates granulomatous-appearing keratic precipitates.

rience visual halos. The presentation of CMV anterior uveitis may be acute, chronic, or recurrent. This condition is most commonly seen in people who are middle aged or older.

CMV anterior uveitis is usually unilateral. However, we recently treated a patient who had bilateral disease but no evidence of immune compromise.

Ocular Exam Findings

Best-corrected visual acuity is usually good at the time of presentation. Patients generally present with 1+ cells and 1+ flare, and they may have stellate or large granulomatous-appearing keratic precipitates. Endotheliitis is common and may produce focal corneal en-

dothelial plaques. IOP elevation is a frequent, but not universal, finding; a minority of patients maintain a normal IOP.

Iris signs. Not all patients develop iris signs. However, iris atrophy may be present and is likely caused by direct invasion of the iris stroma by virus or by ischemic necrosis related to extreme fluctuation in IOP. The atrophy may be sectoral or diffuse in nature, and in many cases, it may be progressive throughout the disease course.

Another possible manifestation of CMV anterior uveitis is iris heterochromia.³

Diagnosis

The diagnosis of CMV anterior uveitis is challenging, as there is considerable overlap in clinical signs between it and the more common HSV- or VZV-relat-

BY MAXWELL ELIA, MD, JOHN J. HUANG, MD, AND PAUL A. GAUDIO, MD.

EDITED BY SHARON FEKRAT, MD, AND INGRID U. SCOTT, MD, MPH.

ed forms of anterior uveitis. In many cases, CMV patients are diagnosed only after having been treated unsuccessfully for chronic herpetic uveitis with acyclovir and topical steroids.

In other cases, the infectious origin might not be recognized initially. For example, a patient was referred to our clinic because his anterior uveitis worsened after initiation of immunosuppression with weekly oral methotrexate, raising the concern for an infectious cause.

Laboratory testing. In order to select the appropriate antiviral medication, it is essential to differentiate among CMV, HSV, and VZV as the causative pathogen. Anterior chamber paracentesis should be performed to obtain aqueous fluid analysis for analysis. Real-time polymerase chain reaction (PCR) is the most sensitive test for the detection of herpesviruses; and testing for CMV, HSV, and VZV—and in some cases, *Toxoplasma gondii*—should be considered, depending on the clinical presentation.⁴

Diagnostic anterior chamber paracentesis typically requires a minimum of 100 μ L as an adequate sample for PCR. However, greater sample volumes improve diagnostic yield and allow for testing of multiple pathogens.

Treatment

In our clinical experience, many patients with suspected herpetic uveitis have good vision at presentation and thus are hesitant to undergo diagnostic paracentesis for PCR analysis. In these

cases, we routinely offer empirical treatment with acyclovir or valacyclovir, topical corticosteroids, cycloplegics, and IOP-lowering agents as needed, even in the absence of laboratory confirmation of HSV or VZV.

Given the rarity of CMV anterior uveitis, this particular member of the herpesvirus family remains low on our differential diagnosis unless a patient fails treatment with acyclovir or valacyclovir. CMV is not sensitive to acyclovir, valacyclovir, or penciclovir. At this stage, if a diagnosis of CMV anterior uveitis is being considered, PCR testing should be performed prior to initiating valganciclovir or ganciclovir.

Antiviral drugs. Both acyclovir and ganciclovir are available as esterified prodrugs, called valacyclovir and valganciclovir, respectively, which are converted to the active drugs when metabolized. The chemical modification through esterification makes these prodrugs more suitable for oral administration, allowing for decreased dosing frequency. Because the less frequent dosing improves patient adherence to treatment, we strongly prefer the use of the val-prodrug whenever allowable by insurance payers.

During initiation of treatment, an induction regimen of valganciclovir (900 mg twice daily) is used; and as the disease becomes quiescent, the drug can be maintained at a once-daily dosage of 900 mg. Rare cases of exacerbations that occur on the maintenance regimen can be addressed by reinitiating twice-daily dosing until control is

achieved. Valganciclovir is maintained for 1 year, at which time it can be discontinued if the eye remains quiet.

Side effects. Although most patients tolerate valganciclovir or ganciclovir well, rare side effects include bone marrow suppression and renal toxicity. For patients on chronic treatment, we recommend periodic blood work to monitor for these side effects.

IOP control. Ocular hypertension resulting from CMV anterior uveitis can usually be managed with glaucoma medications. We typically initiate beta-blockers, alpha-agonists, and carbonic anhydrase inhibitors in a stepwise fashion. We avoid prescribing prostaglandin analogues because of concerns that they may worsen herpetic infections.

Some patients, however, require glaucoma surgery. When surgery is required, we generally prefer the use of tube shunts rather than trabeculectomy, because bleb failure is common in the setting of ocular inflammation.

Corticosteroids. Topical corticosteroids should be used aggressively in the disease process to achieve immediate control of intraocular inflammation. Even in cases of severely elevated IOP, the reduction of inflammation and trabeculitis resulting from aggressive steroid therapy typically leads to an improvement in IOP.

Topical corticosteroids and anti-glaucoma medications can be weaned as inflammation and elevations in eye pressure subside.

1 Chee SP et al. *Am J Ophthalmol.* 2008;145(5):834-840.

2 van Boxtel LA et al. *Ophthalmology.* 2007;114(7):1358-1362.

3 Woo JH et al. *Ocul Immunol Inflamm.* 2015;23(5):378-383.

4 van Doornum GJ et al. *J Clin Microbiol.* 2003;41(2):576-580.

Dr. Elia is a fellow in uveitis and retina at the Eye Disease Consultants in Hartford, Conn.

Dr. Huang and Dr. Gaudio are members of the Connecticut Uveitis Foundation and are clinical associate professors at the Yale University School of Medicine, Department of Ophthalmology and Visual Science. *Relevant financial disclosures:* None.

CMV and Posner-Schlossman Syndrome

Mounting evidence suggests an association between CMV anterior uveitis and Posner-Schlossman syndrome (PSS), also known as glaucomatocyclitic crisis.

Posner and Schlossman first described recurrent bouts of anterior uveitis associated with severely elevated IOP in 1948,¹ but the cause of these attacks remained uncertain. The episodes were unilateral and included keratic precipitates, iris atrophy, anterior chamber inflammatory reaction, and elevated IOP.

Recent studies have demonstrated a high rate of CMV PCR positivity in the anterior chamber taps of patients with PSS, and nearly all reported PSS patients improve with the addition of oral valganciclovir to their antiglaucoma medications. Thus, it is important to maintain a high index of suspicion for CMV anterior uveitis—and to consider PCR testing—in all cases of suspected PSS.

1 Posner A, Schlossman A. *Arch Ophthalmol.* 1948;39(4):517-535.